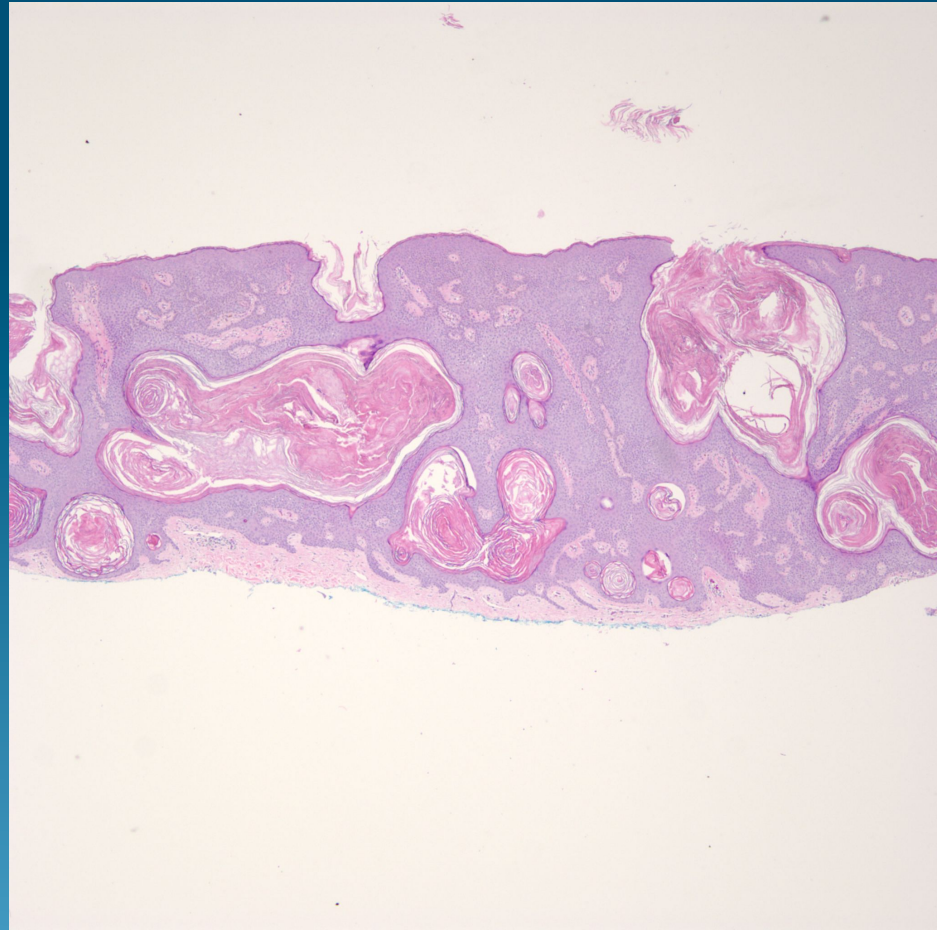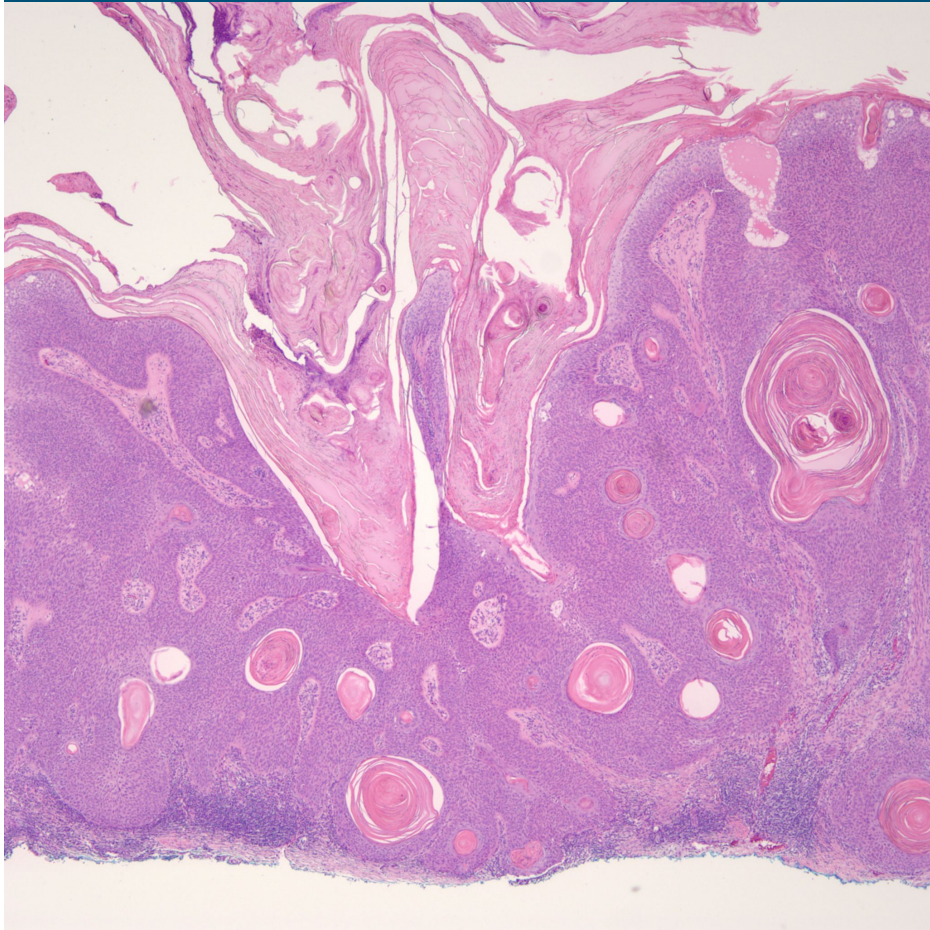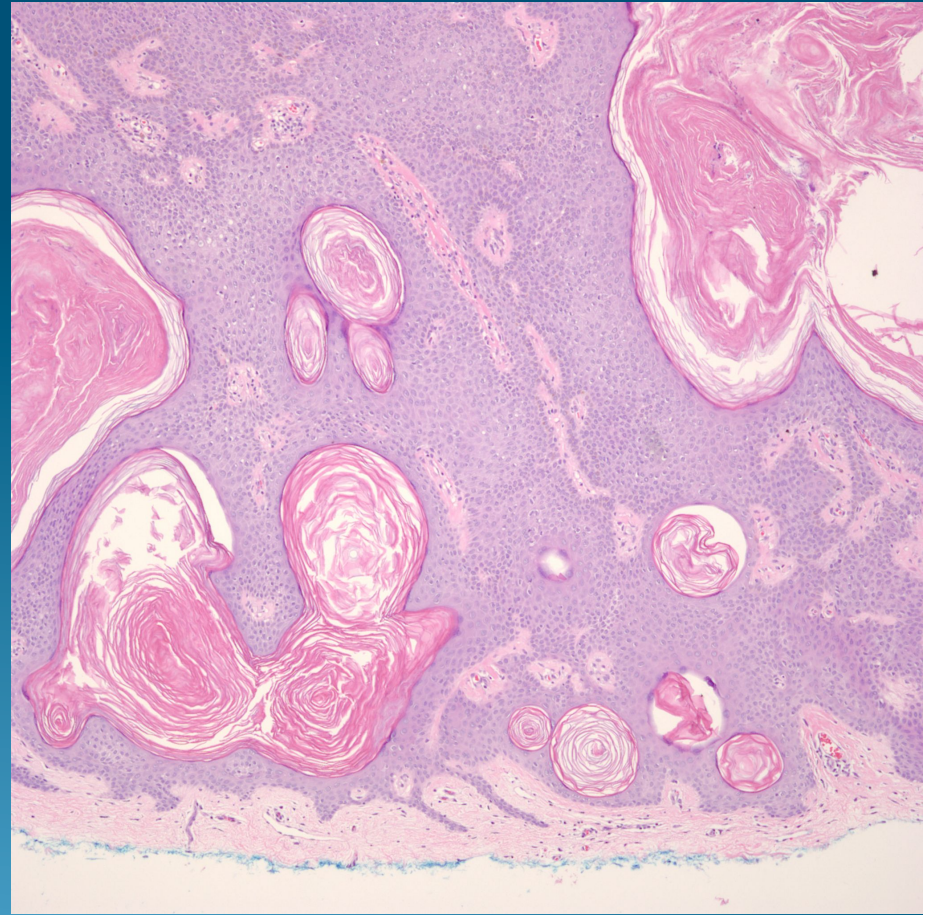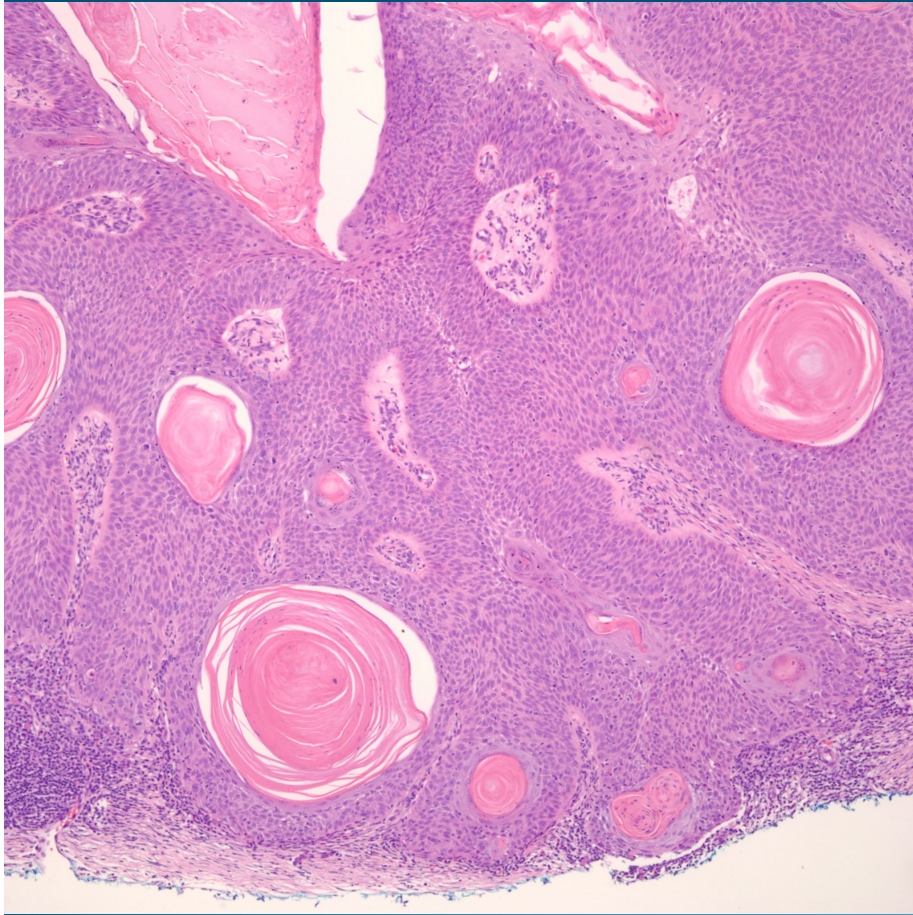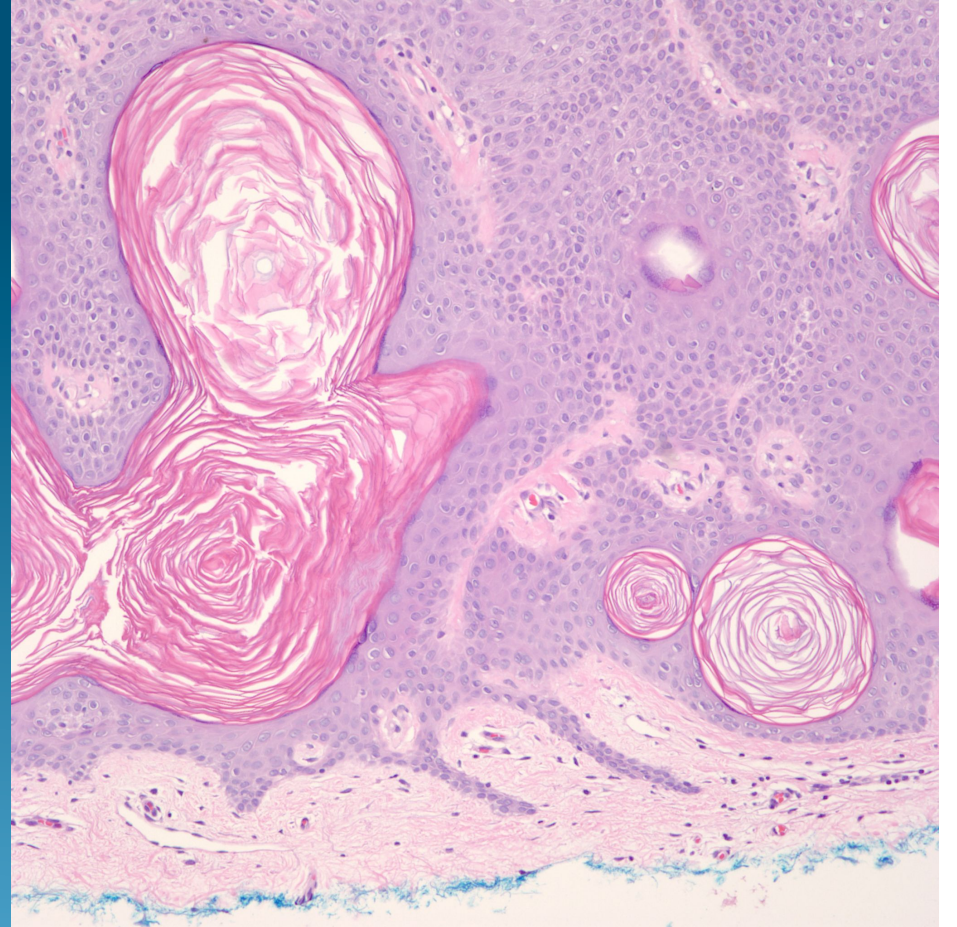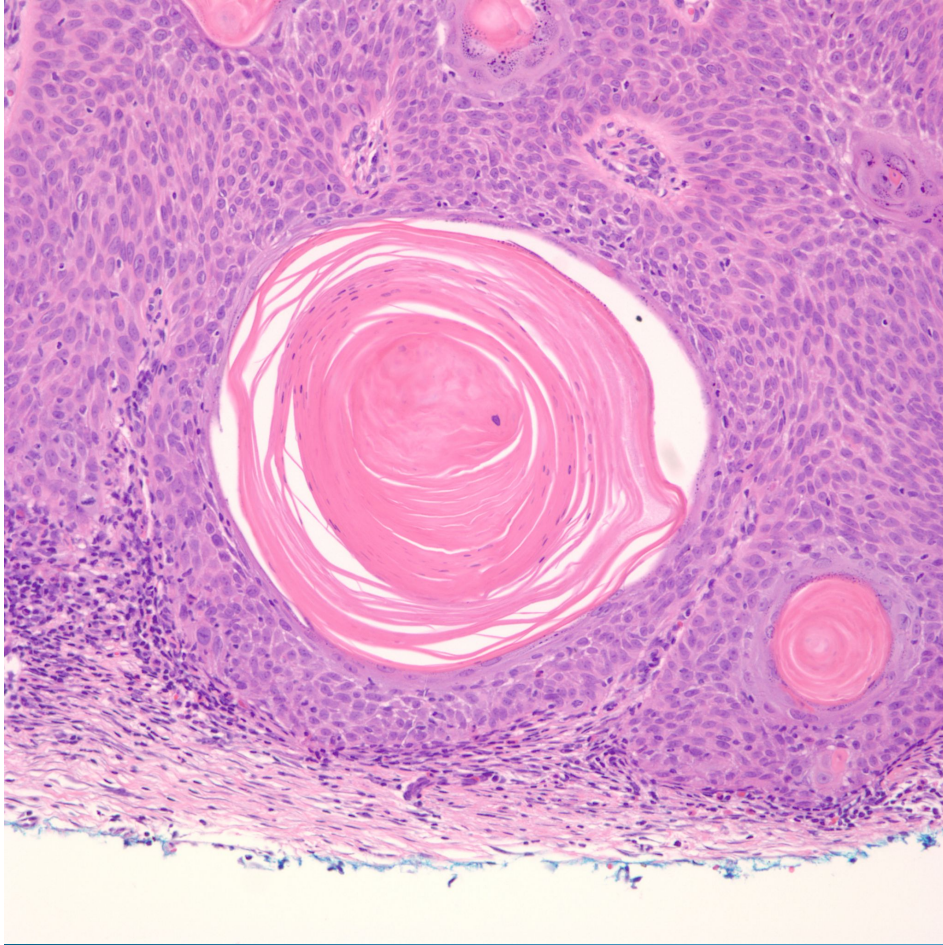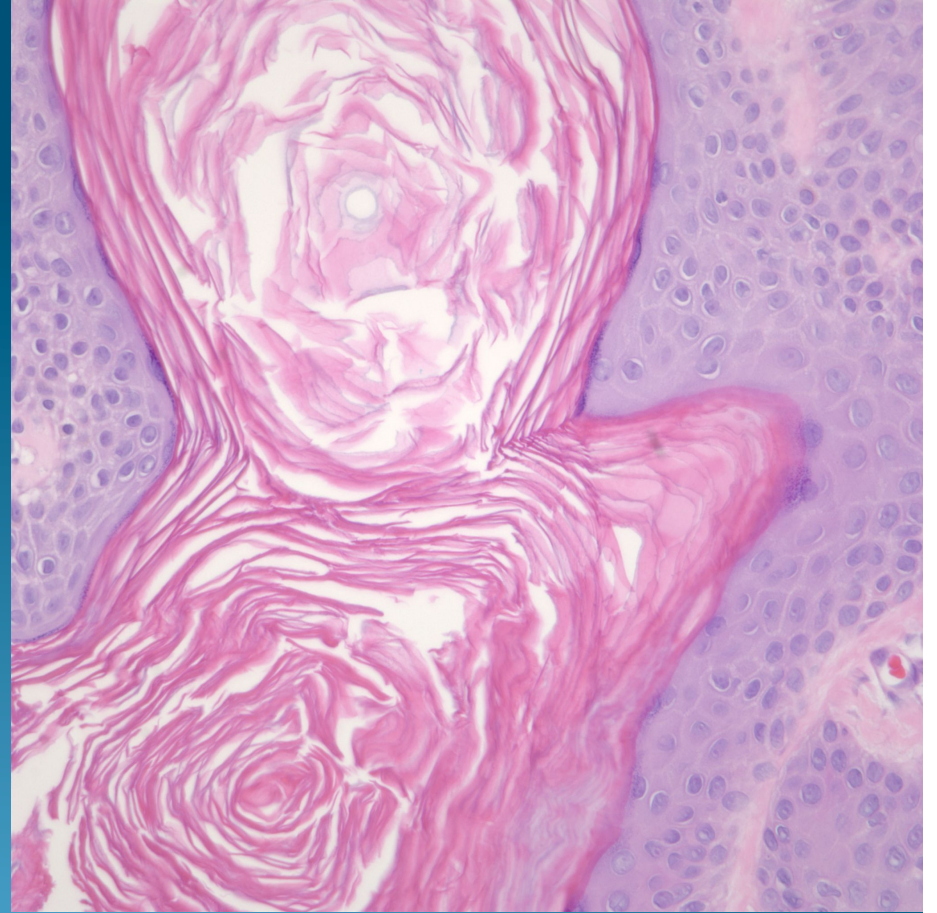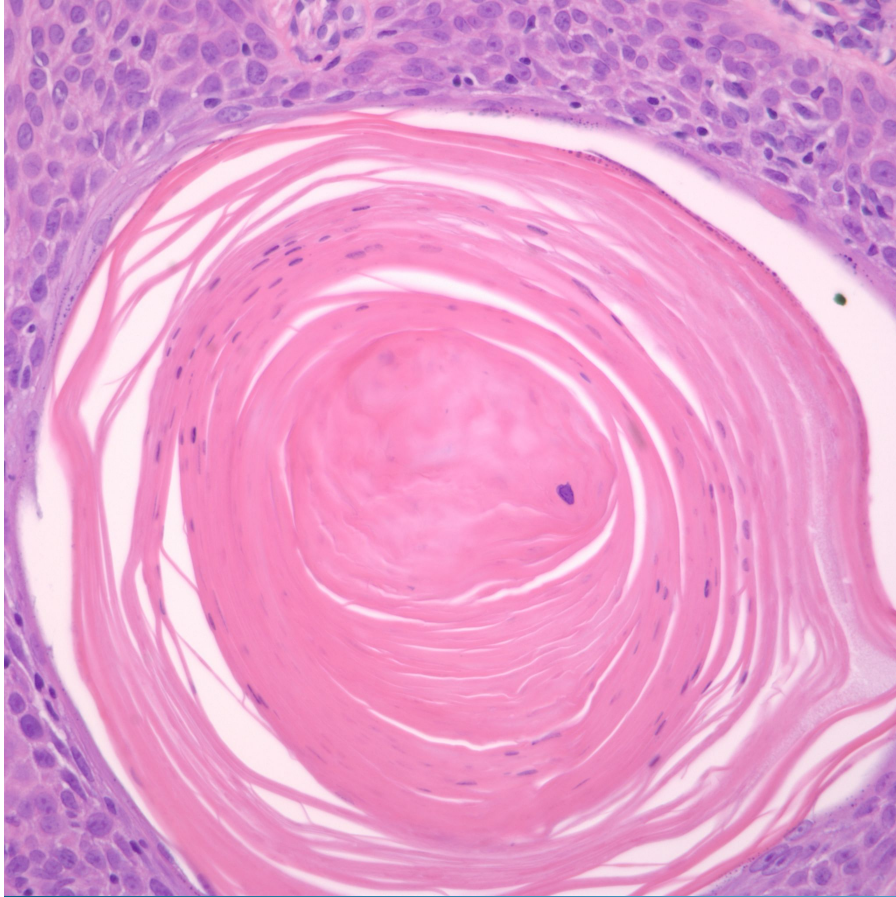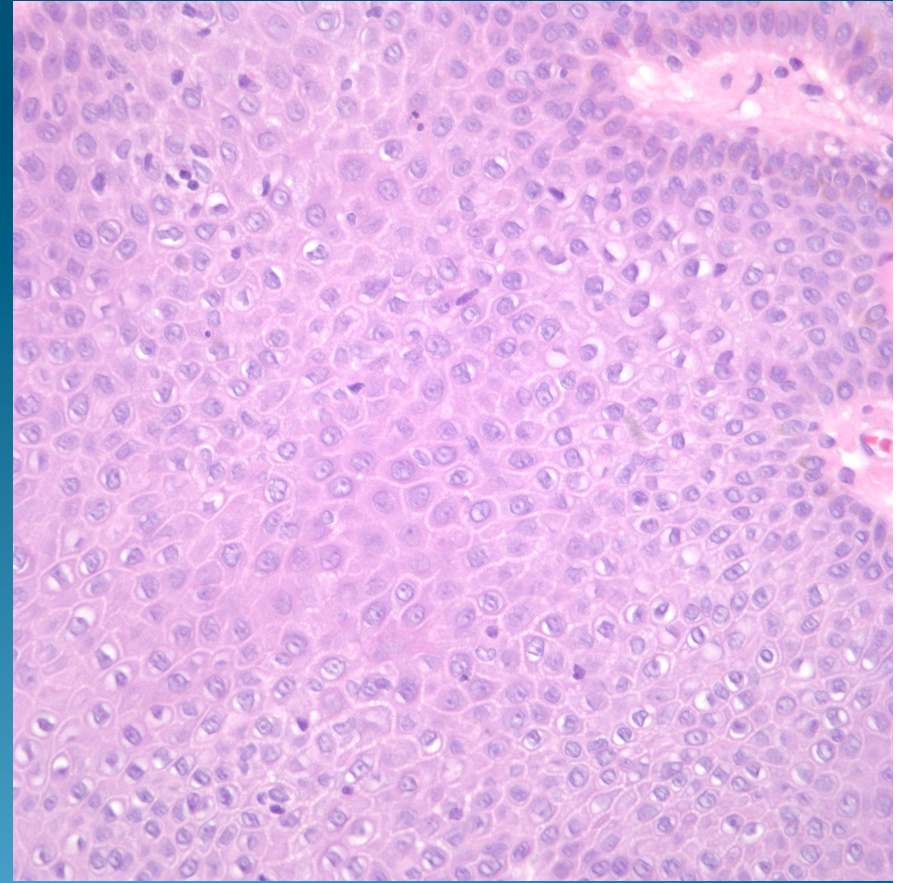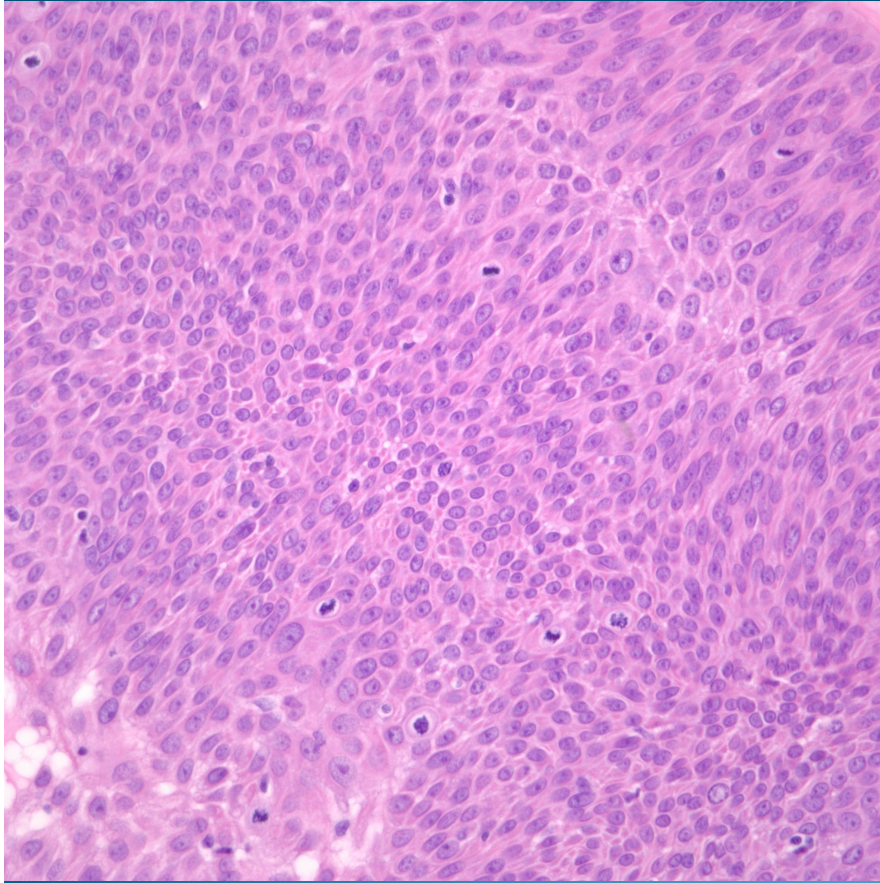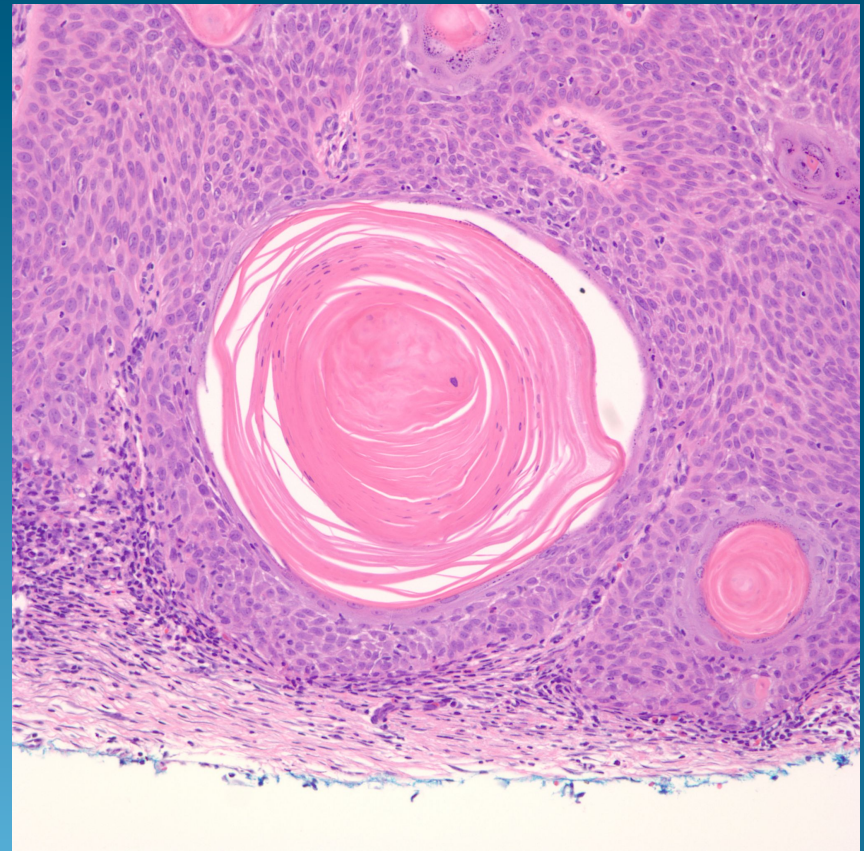
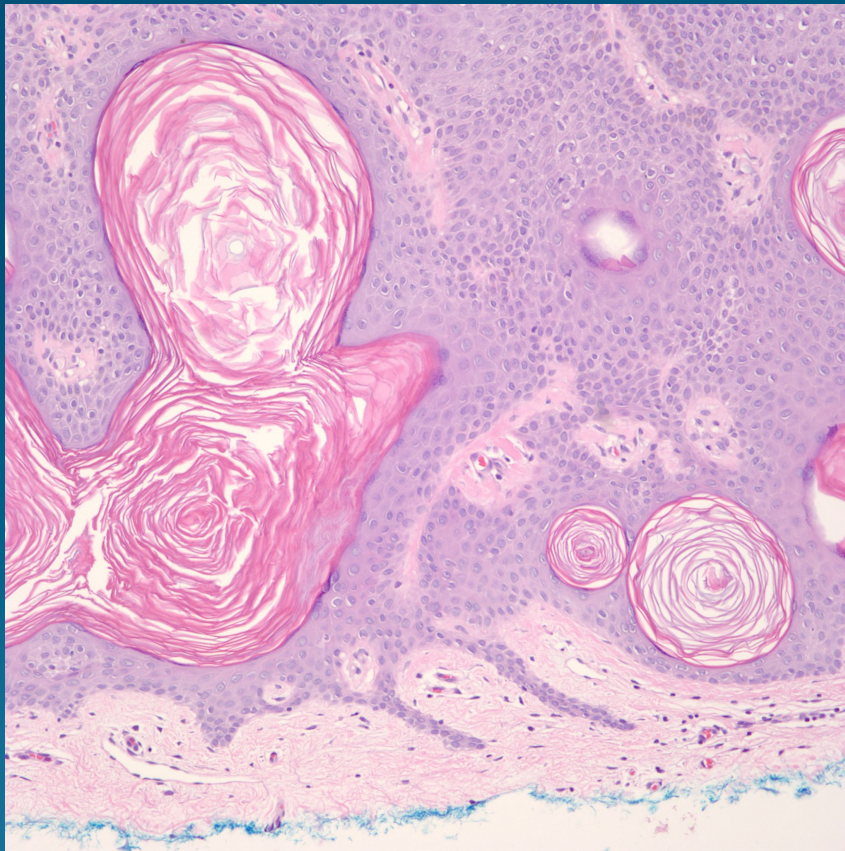
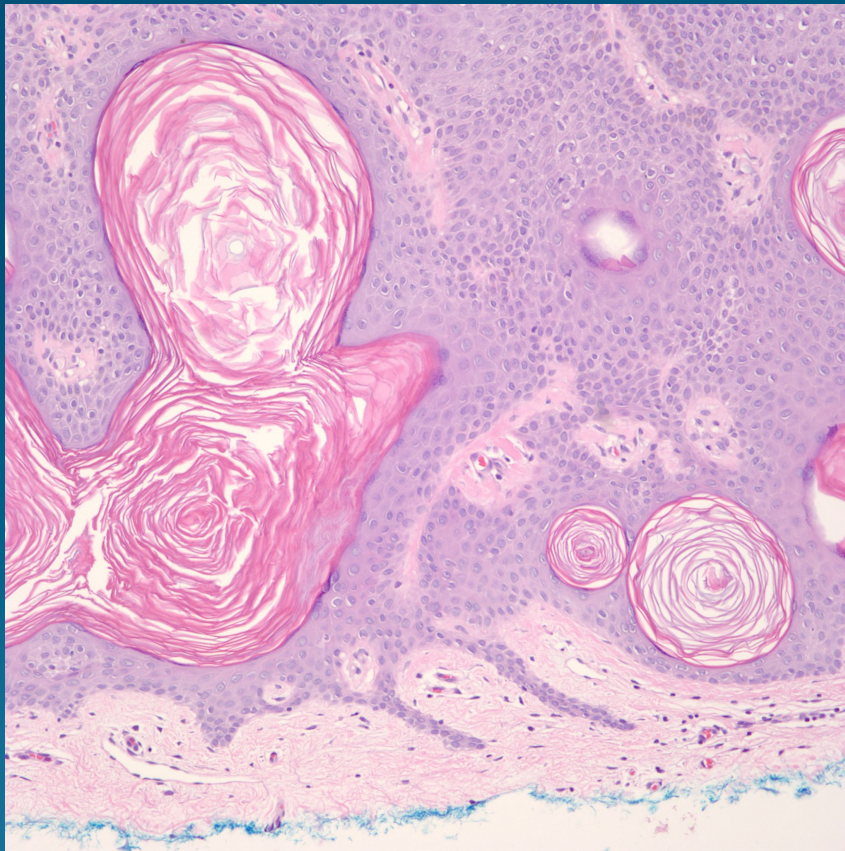


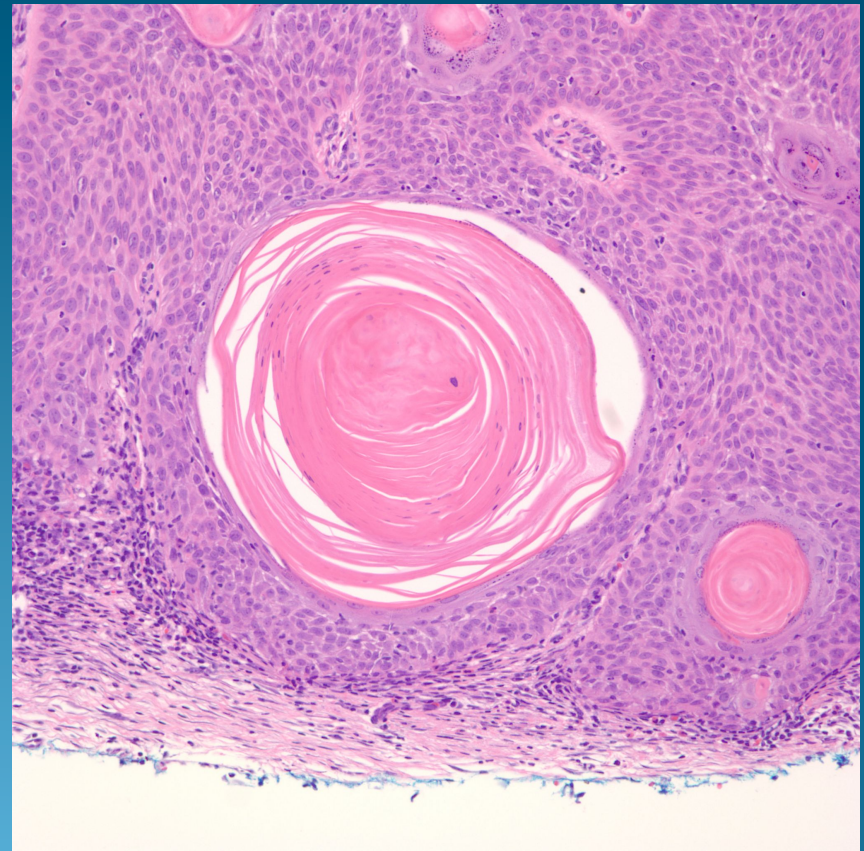
Bowen's Disease or Seborrheic Keratosis?



Seborrheic Keratosis



Bowen's Disease



Pearls

- Seborrheic keratosis has flattened rete ridges
- Horn pseudocysts are invaginations of epidermis with loose keratin with granular layer usually identified
- Minimal atypia of keratinocytes
- Bowen's disease has increased cellularity giving hyperchromasia to epidermis
- Irregular rete ridge pattern
- Squamous pearls with compact keratin and abrupt keratinization with parakeratosis and absent granular layer
- Increased cytologic atypia of keratinocytes with atypical mitotic figures